

# Case Report

## Severe Vivax Malaria: A Case Report and A Literature Review

Dhitiwat Changpradub MD\*,  
Mathirut Mungthin MD, PhD\*\*

\* Division of Infectious Disease, Department of Medicine, Phramongkutklao Hospital, Bangkok, Thailand  
\*\* Department of Parasitology, Phramongkutklao College of Medicine, Bangkok, Thailand

---

Most cases of severe malaria are caused by infection of *Plasmodium falciparum*. However, severe manifestations in the infection of *P. knowlesi* and *P. vivax* have been reported in recent years. The present study reported a 24-year-old Thai male presenting with acute fever and shock. Both blood smears and PCR were positive for *P. vivax*. He was treated with intravenous artesunate for 3 days in combination with oral mefloquine for 2 days and oral primaquine for 14 days. He was discharged from hospital without any sequelae.

**Keywords:** Severe vivax malaria, *Plasmodium vivax*, Shock, Thailand

**J Med Assoc Thai 2014; 97 (Suppl. 2): S243-S246**

**Full text. e-Journal:** <http://www.jmatonline.com>

---

Malaria is a vector-borne infectious disease caused by protozoan parasites, *Plasmodium* spp. Malaria has been a major cause of death and illness in children and adults, especially in tropical countries. The parasites are inoculated into the human host by feeding female anopheline mosquitoes<sup>(1,2)</sup>. Five *Plasmodium* species cause disease in humans and are: *P. falciparum*, *P. vivax*, *P. ovale*, *P. malariae*, and *P. knowlesi*. Among these, *P. falciparum* is the most common cause of severe malaria. Herein, the authors report a case of severe malaria caused by *P. vivax*.

### Case Report

A 24-year-old Thai male had fever with chills for 1 week mostly in the afternoon. He also experienced headache, fatigue, and myalgia. He took two tablets of 500-mg acetaminophen every 6 hours, but the fever remained high. He was brought to a hospital 2 days before admission and was prescribed as an outpatient with an antibiotic and acetaminophen. Six hours prior to admission, he got high fever with loss of appetite and somnolence. He was then returned to the hospital.

At the emergency department, he experienced an alteration of consciousness and tachycardia (heart rate 130 beats/min). His body temperature was 38.5°C,

and his blood pressure was 86/40 mmHg. Upon arrival, he was diagnosed in septic shock. A central venous catheter was used followed by intravenous fluid resuscitation. After resuscitation with 3,000 mL of normal saline solution (NSS), his blood pressure remained low (74/26 mmHg), central venous pressure (CVP) was 9 cm H<sub>2</sub>O. Parenteral antibiotics (Ceftriaxone 2 gm intravenously) and inotropic agent (Norepineprine, Levophed®, 0.1 mcg/kg/min) were then started to maintain his hemodynamic status. Physical examination revealed body temperature of 38.5°C, blood pressure of 86/40 mmHg, pulse rate of 130 beats/min, respiratory rate of 24/min, and oxygen saturation of 99%. His lungs, heart, and abdomen were normal on physical examination. No organomegaly was found. He had stuporous consciousness without any definite focal neurological deficit on examination.

Before this admission, he was in a good health, no other medical conditions. He lived in Sakon Nakhon Province (northeastern region of Thailand). He worked as a billboard painter in Bangkok during the previous 3 weeks. Five months ago, he went hunting in the Pupan Mountain in Sakon Nakhon Province.

Complete blood count revealed Hct 46.3%, Hb 15.4 g/dL, WBC 5,900 cells/mm<sup>3</sup>, Neutrophil 82%, Lymphocyte 13.7%, Monocyte 0.8%, platelet 18,000/mm<sup>3</sup>. Multiple stages of *P. vivax* including trophozoites, schizonts, and gametocytes were detected in the blood smears. His blood chemistry results were as followed: BUN 24 mg/dL, Cr 1.4 mg/dL, Na<sup>+</sup> 137 mmol/L, K<sup>+</sup> 2.75 mmol/L, Cl<sup>-</sup> 99.4 mmol/L, and HCO<sub>3</sub><sup>-</sup> 19.5 mmol/L. The

---

### Correspondence to:

Changpradub D, Division of Infectious Disease, Department of Medicine, Phramongkutklao Hospital, 315 Rajavithi Road Bangkok 10400, Thailand.

Phone: 0-2644-4420

E-mail: [dhitiwat@yahoo.com](mailto:dhitiwat@yahoo.com)

liver function test was Total/Direct Bilirubin 1.2/0.7 mg/dL, SGOT/SGPT 63/137 IU/L, Alkaline Phosphatase 136 IU/L, and Total Protein/albumin 6.4/3.6 g/L. Other investigations showed negative results of PCR for Dengue virus, NS1 Ag, IgM and IgG for Dengue and IgM for Leptospirosis. Immunofluorescent assays (IFA) for Scrub typhus, Murine typhus and Tick typhus showed negative results. There was no growth on blood culture after 5 days.

The authors screened malaria with rapid diagnostic tests using *Plasmodium* spp. Associated Lactate Dehydrogenase (OptiMal test, Diamed AG, Cressier sur Morat, Switzerland) and the result showed only a non-*P. falciparum* band. This sample was confirmed to be *P. vivax* positive by PCR technique as described by Snounou et al (1993)<sup>(3)</sup>. PCR amplification showed a positive band at 120 bp that was compatible with *P. vivax* (Fig. 1). PCR for *P. falciparum* showed a negative result.

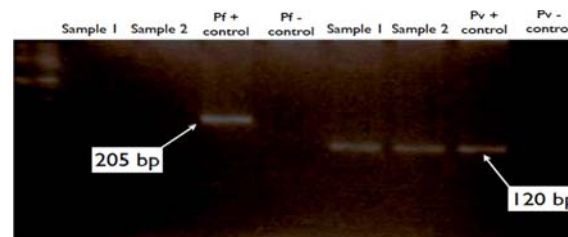
On admission, 2.4 mg/kg of intravenous artesunate was given, then at 12, 24 hours, then once a day with a total of 600 mg. Oral mefloquine 15 mg/kg on the first day and 10 mg/kg on the second day were also given and followed by primaquine 30 mg per day for 14 days. The inotropic agent was also prescribed. His temperature returned to normal within 12 hours after antimalarials were started. His blood pressure became normal within 24 hours. He was discharged from hospital on Day 6 after admission without any sequelae.

## Discussion

The authors here report a case of severe vivax

malaria presenting with shock and mild impairment of both kidney and liver functions. The WHO defines severe malaria by the presence of any of several clinical or laboratory criteria in a patient with asexual form of *P. falciparum* (Table 1)<sup>(1,2)</sup>. Shock is also one of the clinical criteria of severe malaria. This was a confirmed case of mono-infection of *P. vivax* using different diagnostic methods, i.e. microscopic examination, rapid diagnostic test for malaria and PCR. The authors also ruled out as a co-infection of *P. falciparum*, the more common cause of severe malaria, by these tests. Other causes of shock were excluded including dengue shock syndrome, leptospirosis, scrub typhus, murine typhus, tick typhus and bacteremia.

Severe vivax malaria has been described in several literatures from Papua, Indonesia<sup>(4)</sup>. In 1998-2000 (36 months period), there were 5,936 cases of malaria and 1,135 cases were vivax malaria. Among these, 36 cases presented with severe manifestations, and 9



**Fig. 1** PCR amplification for the diagnosis of *P. vivax* infection. Samples from the patient showed positive band at 120 bp which indicated *P. vivax* positive.

**Table 1.** Clinical features and laboratory findings in severe malaria

Clinical features	Laboratory findings
Impaired consciousness or unrousable coma	Hypoglycemia (blood glucose <2.2 mmol/l or <40 mg/dl)
Prostration	Metabolic acidosis (plasma bicarbonate <15 mmol/l)
Failure to feed	Severe normocytic anemia (Hb <5 g/dl, packed cell volume <15%)
Multiple convulsions (>2 episodes in 24 h)	Hemoglobinuria
Deep breathing, respiratory distress (acidotic breathing)	Hyperparasitemia (>2%/100,000/μl in low intensity transmission areas or >5% or 250,000/μl in areas of high stable malaria transmission intensity)
Circulatory collapse or shock, systolic blood pressure <70 mmHg in adults and <50 mmHg in children	Hyperlactatemia (lactate >5 mmol/l)
Clinical jaundice plus evidence of other vital organ dysfunction	Renal impairment (serum creatinine >265 μmol/l)
Hemoglobinuria	
Abnormal spontaneous bleeding	
Pulmonary edema (radiological)	

**Table 2.** Clinical presentation of severe vivax malaria from India, Indonesia and Malaysia

Symptoms	India <sup>(4)</sup> (n = 40)		Indonesia <sup>(3)</sup> (n = 36)		Malaysia <sup>(5)</sup> (n = 7)	
	Case	%	Case	%	Case	%
Jaundice, Liver dysfunction	23	57.5	10	18.2	2	29
Renal failure	18	45.0	4	7.3	NA	NA
Severe anemia	13	32.5	24	43.6	NA	NA
Thrombocytopenia with bleeding	9	22.5	NA	NA	1	14
Cerebral malaria, Multiple seizure	5	12.5	5	9.1	1	14
ARDS	4	10.0	2	3.6	1	14
Shock	3	7.5	NA	NA	5	71
Hypoglycemia	1	2.5	NA	NA	NA	NA
Multi-organ dysfunction	19	47.5	1	1.8	NA	NA
Acidosis	NA	NA	3	5.5	NA	NA

cases died. The most common manifestation is severe anemia (Hb <6 g/dL) which presented in 24 cases (67%). In India<sup>(5)</sup>, there were 1,091 malaria cases during September 2003 through December 2005. Forty cases of mono-infection of vivax malaria that had been confirmed by PCR, experienced severe manifestations. The common presentations were jaundice (serum bilirubin >3 mg/dL), renal failure (creatinine >3 mg/dL) and severe anemia (hemoglobin <5 mg/dL) which presented in 58%, 45% and 32% of the enrolled patients, respectively. Another study from Malaysia<sup>(6)</sup> revealed 387 malaria cases admitted during September 2010 to October 2011. Forty-three patients were diagnosed as vivax malaria. Seven of them had severe manifestations. Hypotension and shock (71%) were the most common presentations among these cases. The other severe manifestations were jaundice, ARDS, bleeding and multiple convulsions (Table 2).

A few pathogenic mechanisms of severe malaria especially the mechanisms of severe anemia were proposed<sup>(7)</sup>. These included the destruction of non-infected RBCs, invasion and destruction of reticulocytes, increased fragility of infected and non-infected RBCs. Cytokines production is another pathogenic mechanism of severe vivax malaria. There was relatively more cytokine production when compared to *P. falciparum* infection which may cause organ-specific inflammation, including increased alveolar-capillary membrane permeability and acute lung injury and greater hemodynamic compromised in the setting of acute or chronic co-morbidity<sup>(8-11)</sup>.

### Conclusion

The present study reported a severe case of

vivax malaria in a 24-year-old man who presented with shock. It is a rare manifestation in vivax malaria but exists. Before a diagnosis of this syndrome is made, a few infectious diseases including falciparum malaria and other tropical infectious diseases should be excluded.

### Potential conflicts of interest

None.

### References

1. World Health Organization, Communicable Diseases Cluster. Severe falciparum malaria. *Trans R Soc Trop Med Hyg* 2000; 94 (Suppl 1): S1-90.
2. Hoffman SL, Campbell CC, White NJ. Malaria. In: Guerrant RL, Walker DH, Weller PF, editors. *Tropical infectious diseases: principles, pathogens, & practice*. 2<sup>nd</sup> ed. Philadelphia: Churchill Livingstone; 2006: 1024-62.
3. Snounou G, Viriyakosol S, Jarra W, Thaithong S, Brown KN. Identification of the four human malaria parasite species in field samples by the polymerase chain reaction and detection of a high prevalence of mixed infections. *Mol Biochem Parasitol* 1993; 58: 283-92.
4. Barcus MJ, Basri H, Picarima H, Manyakori C, Sekartuti, Elyazar I, et al. Demographic risk factors for severe and fatal vivax and falciparum malaria among hospital admissions in northeastern Indonesian Papua. *Am J Trop Med Hyg* 2007; 77: 984-91.
5. Kochar DK, Das A, Kochar SK, Saxena V, Sirohi P, Garg S, et al. Severe Plasmodium vivax malaria: a report on serial cases from Bikaner in northwestern

- India. Am J Trop Med Hyg 2009; 80: 194-8.
6. Barber BE, William T, Grigg MJ, Menon J, Auburn S, Marfurt J, et al. A prospective comparative study of knowlesi, falciparum, and vivax malaria in Sabah, Malaysia: high proportion with severe disease from Plasmodium knowlesi and Plasmodium vivax but no mortality with early referral and artesunate therapy. Clin Infect Dis 2013; 56: 383-97.
  7. Wickramasinghe SN, Looareesuwan S, Nagachinta B, White NJ. Dyserythropoiesis and ineffective erythropoiesis in Plasmodium vivax malaria. Br J Haematol 1989; 72: 91-9.
  8. Tan LK, Yacoub S, Scott S, Bhagani S, Jacobs M. Acute lung injury and other serious complications of Plasmodium vivax malaria. Lancet Infect Dis 2008; 8: 449-54.
  9. Suratt BT, Parsons PE. Mechanisms of acute lung injury/acute respiratory distress syndrome. Clin Chest Med 2006; 27: 579-89.
  10. Anstey NM, Handojo T, Pain MC, Kenangalem E, Tjitra E, Price RN, et al. Lung injury in vivax malaria: pathophysiological evidence for pulmonary vascular sequestration and posttreatment alveolar-capillary inflammation. J Infect Dis 2007; 195: 589-96.
  11. Anstey NM, Russell B, Yeo TW, Price RN. The pathophysiology of vivax malaria. Trends Parasitol 2009; 25: 220-7.

---

## การติดเชื้อมาลาเรียชนิดรุนแรงจากพลาสโมเดียม ไวแวกซ์

ฐิติวัฒน์ ช่างประดับ, มทิวรุต มุ่งฉิม

มาลาเรียชนิดรุนแรงส่วนใหญ่เกิดจากการติดเชื้อ *Plasmodium falciparum* แต่มีรายงานการเกิดมาลาเรียชนิดรุนแรงจากการติดเชื้อ *P. knowlesi* และ *P. vivax* ในช่วงหลายปีที่ผ่านมาในครั้งนี้ ผู้เขียนได้รายงานผู้ป่วยชายไทยอายุ 24 ปีมีอาการไข้สูงร่วมกับภาวะช็อค จากการตรวจเลือดและ PCR พบว่ามีเชื้อ *P. vivax* หลังทำการรักษาด้วยยา artesunate ชนิดฉีดเข้าหลอดเลือดดำร่วมกับยารับประทาน mefloquine และ primaquine หลังการรักษาผู้ป่วยสามารถออกจากโรงพยาบาลอย่างปลอดภัย

---